

SONO case series: right upper quadrant point-of-care ultrasound in assessment of the gallbladder

CASE PRESENTATION

A woman aged 44 years with a history of endometrial adenocarcinoma, for which she had a total abdominal hysterectomy and bilateral salpingo-oophorectomy, presents to the ED with 2 days of intermittent right-sided abdominal pain radiating to the epigastrium and right flank. The pain is exacerbated by eating fatty foods. Of note, patient reported intermittent right lower quadrant abdominal pain to an outpatient provider 3 months prior, and a CT was ordered to evaluate for cancer recurrence. The CT scan was performed 1 week prior to this ED visit and showed no acute pathology in the abdomen or pelvis, including an unremarkable gallbladder.

On initial evaluation, the patient is non-toxic appearing, with vital signs of temperature 36.8°C (98.2°F), pulse 76 beats/min, BP 143/101 mm Hg, RR 16 breaths/min and oxygen saturation of 100% on room air. The patient's cardiovascular and pulmonary exams are unremarkable. Examination of the abdomen reveals right-sided abdominal tenderness to palpation without rebound, guarding or costovertebral angle tenderness. Basic laboratory tests reveal aspartate transaminase 199 (reference range 10–41 U/L), alanine transaminase 137 (reference range 7–35 U/L) and alkaline phosphatase 102 (reference range 42–98 U/L), and a right upper quadrant (RUQ) point-of-care ultrasound (POCUS) was performed.

WHAT ARE THE INDICATIONS FOR PERFORMING RUQ POCUS?

Common indications for RUQ POCUS include abdominal pain, right-sided flank pain, jaundice and some cases of sepsis.^{1,2} The primary application of ED RUQ POCUS is to assess for the presence of gallstones as well as for evidence of acute cholecystitis, as biliary pathology is a common cause of abdominal pain presentations to the ED.^{1,3} For our patient, the differential diagnosis included hepatobiliary pathology, pyelonephritis, pancreatitis, appendicitis, nephrolithiasis, acute coronary syndrome and pulmonary embolus.

WHICH TRANSDUCER IS BEST SUITED FOR PERFORMING RUQ POCUS?

The curvilinear transducer, a low frequency probe with a large surface area, is preferred for its greater tissue penetration.

WHAT VIEWS SHOULD BE OBTAINED WHEN ASSESSING THE RUQ?

The first step in RUQ POCUS is to identify the gallbladder. Multiple approaches can be used but two are offered here:

1. *Subcostal sweep*: place the probe in a sagittal fashion (probe marker towards the patient's head) and sweep along the right subcostal margin. It may be helpful to begin at the right flank, identifying the liver and right kidney, and sweep medially and cephalad until the gallbladder comes into view. Alternatively, it may be helpful to start at the epigastrium, identifying the inferior edge of the liver and sweeping laterally until the gallbladder comes into view.

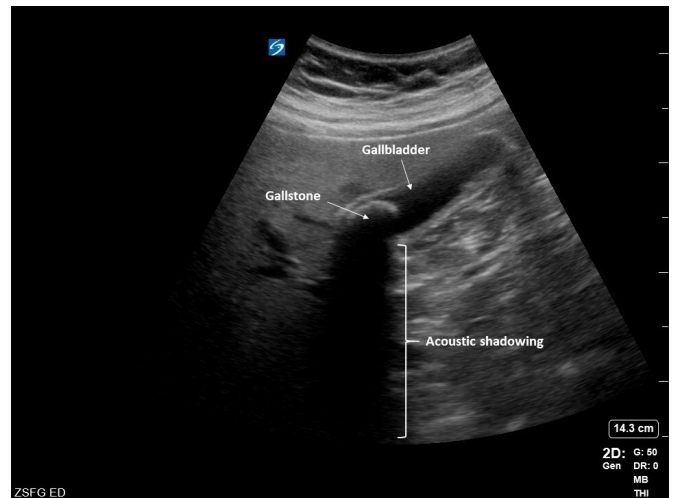

Figure 1 Longitudinal view of the gallbladder from the neck through the fundus of the gallbladder revealing a large stone near the gallbladder neck with associated acoustic shadowing below.

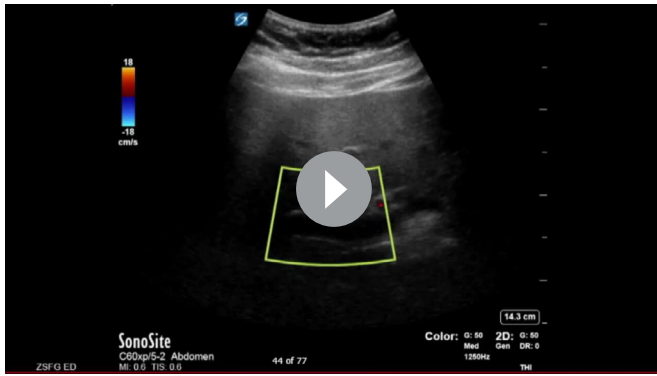
2. *'X minus 7'* (*xiphoid process minus 7*): holding the probe in a transverse orientation (probe marker towards the patient's right), place the probe 7 cm lateral to the xiphoid process in between rib spaces over the liver. Fan through the liver parenchyma until the gallbladder is identified.

Once the gallbladder has been identified, the operator should try to obtain views of the gallbladder in both a longitudinal (figure 1) and transverse (figure 2) orientation. The longitudinal view should showcase the gallbladder from the fundus through the gallbladder neck. The operator should fan through the gallbladder in both these orientations, visualising and investigating the entire gallbladder.

A complete RUQ POCUS includes assessing for (1) the presence of gallstones, identified as hyperechoic or bright white structures with acoustic shadow (an absence of echogenicity deep to the hyperechoic structure); (2) enlargement of the gallbladder, defined as >10 cm by 4 cm; (3) anterior gallbladder wall thickening (>3 mm); (4) pericholecystic fluid, which appear as anechoic or hypoechoic regions surrounding the gallbladder, most commonly along the anterior wall abutting the hepatic

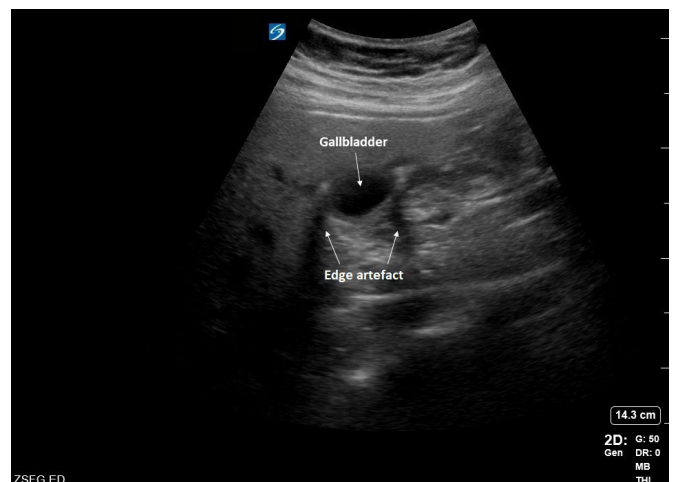

Figure 2 Transverse view of gallbladder with edge artefact, a thin, linear shadowing phenomenon that can occur at the margins of curved structures.



Video 1 Common bile duct visualised above the portal vein with Doppler confirmation, with the hepatic artery also in view.

parenchyma; (5) common bile duct dilation (usually >7 mm) and (6) a sonographic Murphy’s sign, defined as the maximal point of tenderness with the probe pressing over the visualised gallbladder.⁴⁻⁶

The presence of gallstones alone supports the diagnosis of cholelithiasis, while additional findings of gallbladder enlargement, gallbladder wall thickening, pericholecystic fluid and/or sonographic Murphy’s sign suggesting acute cholecystitis. Gallbladder enlargement is one of the earliest signs of cholecystitis. Common bile duct dilation can be a feature of choledocholithiasis or other obstructive biliary pathologies.

Identification of the common bile duct can be facilitated by identifying the portal triad in transverse view by following the gallbladder neck. The common bile duct diameter should be measured in longitudinal view with the common bile duct above the portal vein (video 1). The use of colour mode can distinguish the common bile duct from the portal vein and hepatic artery by the absence of flow. Instead, the presence of flow in this structure would indicate identification of the hepatic artery.

WHAT IS THE INTERPRETATION OF THIS PATIENT’S ULTRASOUND?

A large gallstone, with a hyperechoic surface and acoustic shadowing deep to the stone, was identified at the gallbladder neck (figure 1). The gallbladder wall was not thickened (figure 3).

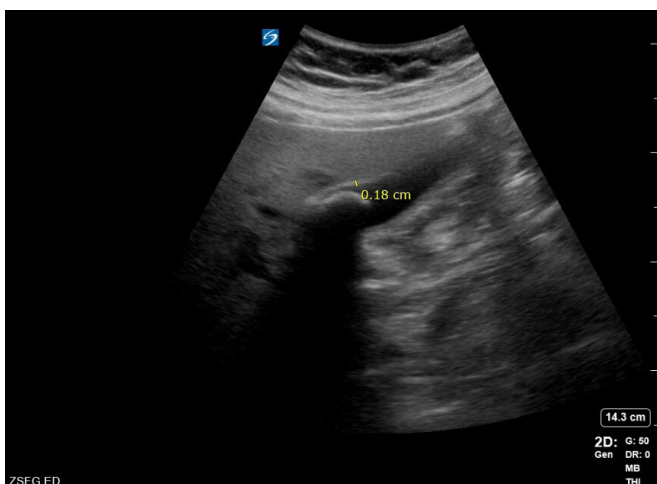


Figure 3 Still image showing a normal measurement, 0.18 cm, of the anterior gallbladder wall. The anterior gallbladder wall is defined as thickened if measuring >0.3 cm.

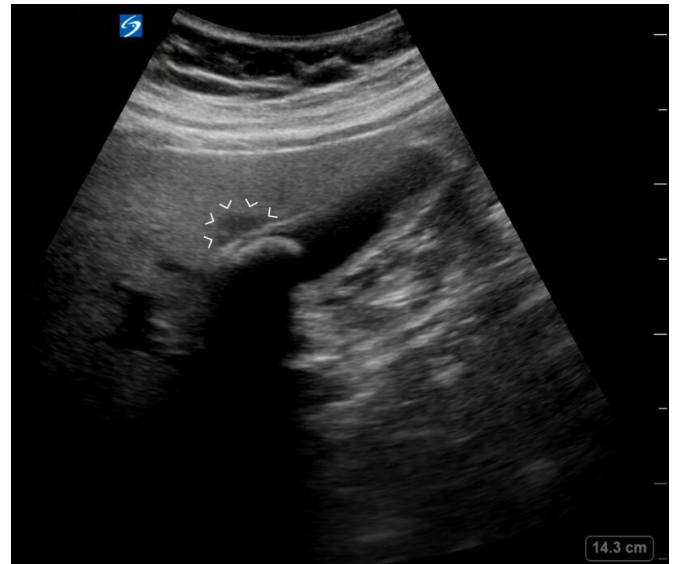

Figure 4 Area of hypoechoogenicity (white arrow heads) along the anterior portion of the gallbladder, more likely representing focal fatty liver sparing than pericholecystic fluid.

There was a small, hypochoic area between the gallbladder and liver that was initially suggestive of pericholecystic fluid, however more likely represents focal fatty liver sparing in this patient with likely hepatic steatosis (figure 4).⁷ The common bile duct measured at 4 mm and was not considered dilated (figure 5). There was no sonographic Murphy’s sign on examination. Given these findings, the patient was presumptively diagnosed with symptomatic cholelithiasis versus acute cholecystitis.

A radiology performed RUQ ultrasound was performed on hospital day 1, demonstrating at least a 2.5 cm shadowing gallstone within the gallbladder neck, as well as a few small gallstones near the fundus. The gallbladder wall appeared mildly thickened; however, the gallbladder was noted to be contracted. No pericholecystic fluid was noted.

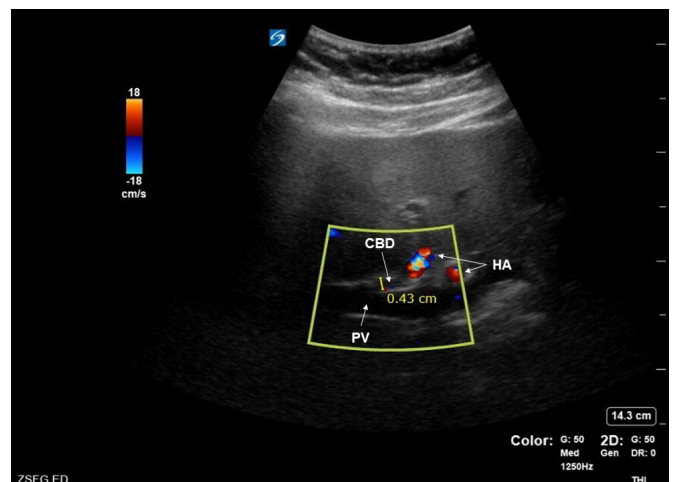


Figure 5 Still image of a measurement of the common bile duct (CBD) in the longitudinal view. The CBD can be visualised in various ways; however, the CBD is predictably found just superior to the portal vein (PV). The portal triad is completed with the hepatic artery (HA), which is shown in close approximation.

WHAT IS THE EVIDENCE FOR USING RUQ POCUS IN CLINICAL PRACTICE?

Ultrasonography is the imaging modality of choice for evaluating biliary pathology, and is recommended as part of the diagnostic bundle for acute cholecystitis by the current World Society of Emergency Surgery guidelines.^{1 8–10} In the ED, RUQ POCUS is becoming a core diagnostic tool in the workup of abdominal pain. A 2011 systematic review found ED RUQ POCUS to have a sensitivity of 90% and specificity of 88% in diagnosing cholelithiasis, and a recent 2021 study found the sensitivity and specificity of ED RUQ POCUS to approach 95% and 93%, respectively.^{11 12} For acute cholecystitis, ED RUQ POCUS is estimated to be 67%–87% sensitive and 82%–97.6% specific.^{6 12} Previous studies have documented the predictive value of gallstones plus sonographic Murphy's sign, gallbladder wall thickening or pericholecystic fluid.^{6 13 14}

While there is ongoing discussion regarding the diagnostic accuracy of POCUS compared with radiology-performed ultrasound or CT for cholecystitis, POCUS offers a short study time, is correlated with a shorter ED length of stay and precludes the need to transport patients out of their rooms.^{13 15–17} These benefits may be attenuated by the skill of the operator and limited consultant confidence,¹⁸ although some evidence suggests similar test characteristics between ED RUQ POCUS and radiology-performed studies.⁶

WHAT ARE SOME PITFALLS OF PERFORMING RUQ POCUS?

1. *Interpreting a negative CT abdomen/pelvis as negative for biliary pathology:* Importantly, negative CT scans do not obviate the need to evaluate the biliary tract, as gallstones isodense with bile may be missed by CT.¹⁹ With ongoing improvements in ultrasound technology, training and application in the ED, practitioners should not rely on a negative CT of the abdomen to exclude biliary pathology. However, CT can be used as an adjunct to evaluate for complications of acute cholecystitis, including emphysematous cholecystitis or gallstone ileus, and can serve as a helpful imaging modality when ultrasound views are limited.^{20 21}
2. *Incomplete assessment of the gallbladder and/or common bile duct:* As reviewed above, a complete RUQ POCUS includes visualisation of the gallbladder in both the longitudinal and transverse orientations with videos sweeping through the entire structure and an assessment for the presence of gallstones, anterior gallbladder wall thickening, pericholecystic fluid, common bile duct dilation and a sonographic Murphy's sign. Visualisation of the gallbladder neck is required, as stones in the neck are more likely to become symptomatic but are more technically difficult to visualise. Identification of the common bile duct may not be possible and is often a challenging part of the RUQ POCUS. Bowel gas and other image optimisation issues (eg, mode, depth, gain) can contribute to difficulty obtaining adequate studies.
3. *Be careful of mimics:* The duodenum, stomach or other fluid-filled structures such as vasculature or solid organ cysts may be mistaken for the gallbladder. A contracted gallbladder can cause the gallbladder wall to appear thickened. Gallbladder polyps and folds may be confused for stones and can often be distinguished by the absence of shadowing as well as immobility, as polyps and folds do not shift with patient repositioning. However, gallstones stuck in the gallbladder neck may not move. In patients with hepatic steatosis, liver parenchyma surrounding the gallbladder can be an area of focal fatty sparing that can mimic pericholecystic fluid.

4. *Anchoring bias:* The presence of cholelithiasis does not necessarily rule out other life-threatening causes of abdominal pain.

CASE CONCLUSION

After the RUQ biliary POCUS, general surgery was consulted for concern for symptomatic cholelithiasis versus acute cholecystitis. Due to ongoing pain, the patient was admitted to the general surgery service and an uncomplicated cholecystectomy was performed on hospital day 3. Intraoperative and pathology findings were consistent with acute cholecystitis. The patient was discharged the day after surgery and recovered well postoperatively.

Elaine Hsiang , Sally Graglia

Emergency Medicine, University of California San Francisco, San Francisco, California, USA

Correspondence to Dr Elaine Hsiang, Emergency Medicine, University of California San Francisco, San Francisco, CA 94143, USA; elaine.hsiang@ucsf.edu

Acknowledgements The authors would like to thank Dr William Shyy who contributed to manuscript revisions.

Contributors EH and SG obtained the original images and video, and drafted and finalised the manuscript.

Funding The authors have not declared a specific grant for this research from any funding agency in the public, commercial or not-for-profit sectors.

Competing interests None declared.

Patient consent for publication Consent obtained directly from patient(s).

Ethics approval This study involves human participants but was not approved by any Ethics Committee(s) or Institutional Board(s). Case report with full written consent was obtained by patient, uploaded with manuscript submission. Participants gave informed consent to participate in the study before taking part.

Provenance and peer review Not commissioned; externally peer reviewed.

© Author(s) (or their employer(s)) 2022. No commercial re-use. See rights and permissions. Published by BMJ.

Handling editor Simon Carley

Emerg Med J 2022;39:479–482.doi:10.1136/emered-2021-211923

ORCID iD

Elaine Hsiang <http://orcid.org/0000-0002-1393-8204>

REFERENCES

- 1 American College of Emergency Physicians. Emergency ultrasound imaging criteria compendium, 2014. Available: <https://www.acep.org/patient-care/policy-statements/Emergency-Ultrasound-Imaging-Criteria-Compendium/> [Accessed 7 Mar 2021].
- 2 ACEP now. bedside biliary ultrasound, 2010. Available: <https://www.acepnow.com/article/bedside-biliary-ultrasound/> [Accessed 30 May 2021].
- 3 Cervellin G, Mora R, Ticinesi A, et al. Epidemiology and outcomes of acute abdominal pain in a large urban emergency department: retrospective analysis of 5,340 cases. *Ann Transl Med* 2016;4:362.
- 4 Parulekar SG. Ultrasound evaluation of common bile duct size. *Radiology* 1979;133:703–7.
- 5 Lahham S, Becker BA, Gari A, et al. Utility of common bile duct measurement in ED point of care ultrasound: a prospective study. *Am J Emerg Med* 2018;36:962–6.
- 6 Summers SM, Scruggs W, Menchine MD, et al. A prospective evaluation of emergency department bedside ultrasonography for the detection of acute cholecystitis. *Ann Emerg Med* 2010;56:114–22.
- 7 O'Donnell C. Focal fatty sparing of the liver. *Radiopaedia*, 2015. Available: <https://radiopaedia.org/cases/focal-fatty-sparing-of-the-liver> [Accessed 9 Aug 2021].
- 8 American College of Emergency Physicians. Ultrasound guidelines: emergency, point-of-care, and clinical ultrasound guidelines in medicine, 2016. Available: <https://www.acep.org/patient-care/policy-statements/ultrasound-guidelines-emergency-point-of-care-and-clinical-ultrasound-guidelines-in-medicine/> [Accessed 6 Mar 2021].
- 9 Yarmish GM, Smith MP, Rosen MP, et al. ACR appropriateness criteria right upper quadrant pain. *J Am Coll Radiol* 2014;11:316–22.
- 10 Pisano M, Allievi N, Gurusamy K, et al. 2020 world Society of emergency surgery updated guidelines for the diagnosis and treatment of acute calculus cholecystitis. *World J Emerg Surg* 2020;15:1–26.

- 11 Ross M, Brown M, McLaughlin K, *et al.* Emergency physician-performed ultrasound to diagnose cholelithiasis: a systematic review. *Acad Emerg Med* 2011;18:227–35.
- 12 Sharif S, Vlahaki D, Skitch S. Evaluating the diagnostic accuracy of point-of-care ultrasound for cholelithiasis and cholecystitis in a Canadian emergency department. *Can J Emerg Med* 2021;1–5.
- 13 Kendall JL, Shimp RJ. Performance and interpretation of focused right upper quadrant ultrasound by emergency physicians. *J Emerg Med* 2001;21:7–13.
- 14 Jang TB, Ruggeri W, Kaji AH. The predictive value of specific emergency sonographic signs for cholecystitis. *J Med Ultrasound* 2013;21:29–31.
- 15 Hilsden R, Leeper R, Koichopolos J, *et al.* Point-Of-Care biliary ultrasound in the emergency department (BUSED): implications for surgical referral and emergency department wait times. *Trauma Surg Acute Care Open* 2018;3:e000164.
- 16 Blaivas M, Harwood RA, Lambert MJ. Decreasing length of stay with emergency ultrasound examination of the gallbladder. *Acad Emergency Med* 1999;6:1020–3.
- 17 Hiatt KD, Ou JJ, Childs DD. Role of ultrasound and CT in the workup of right upper quadrant pain in adults in the emergency department: a retrospective review of more than 2800 cases. *Am J Roentgenol* 2020;214:1305–10.
- 18 Hansen W, Mitchell CE, Bhattarai B, *et al.* Perception of point-of-care ultrasound performed by emergency medicine physicians. *J Clin Ultrasound* 2017;45:408–15.
- 19 Hastings RS, Powers RD. Abdominal pain in the ED: a 35 year retrospective. *Am J Emerg Med* 2011;29:711–6.
- 20 Pinto A, Reginelli A, Cagini L, *et al.* Accuracy of ultrasonography in the diagnosis of acute calculous cholecystitis: review of the literature. *Crit Ultrasound J* 2013;5.
- 21 Revzin MV, Scutt LM, Garner JG, *et al.* Right upper quadrant pain: ultrasound first! *J Ultrasound Med* 2017;36:1975–85.